



X-ray Case Discussion

X-ray discussion

Say what you see

Think about co-morbidities

Think about patient age

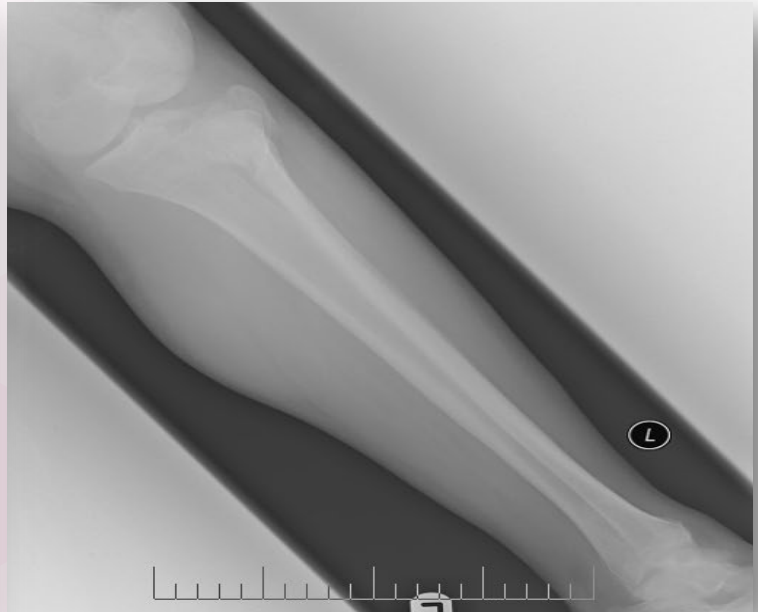
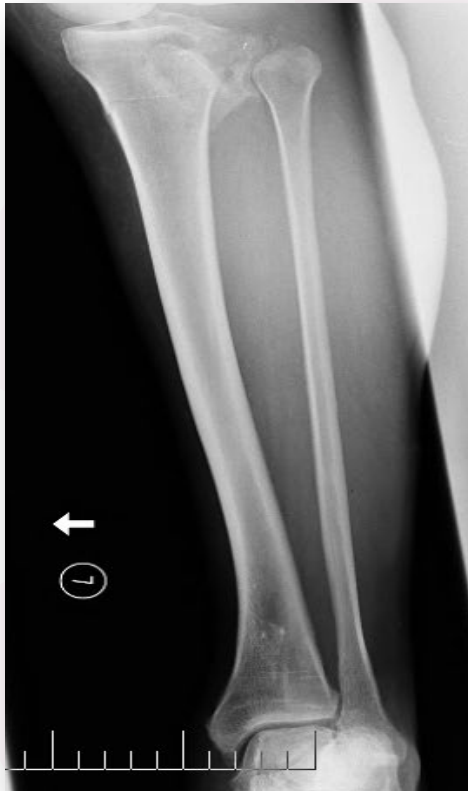Discuss different fixation options

Consider the whole x-ray, not just the fracture

What factors could influence surgeon decision?

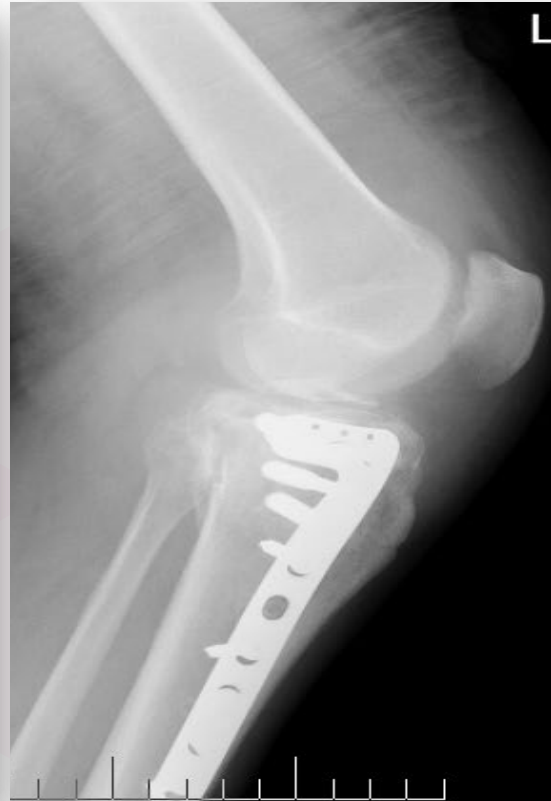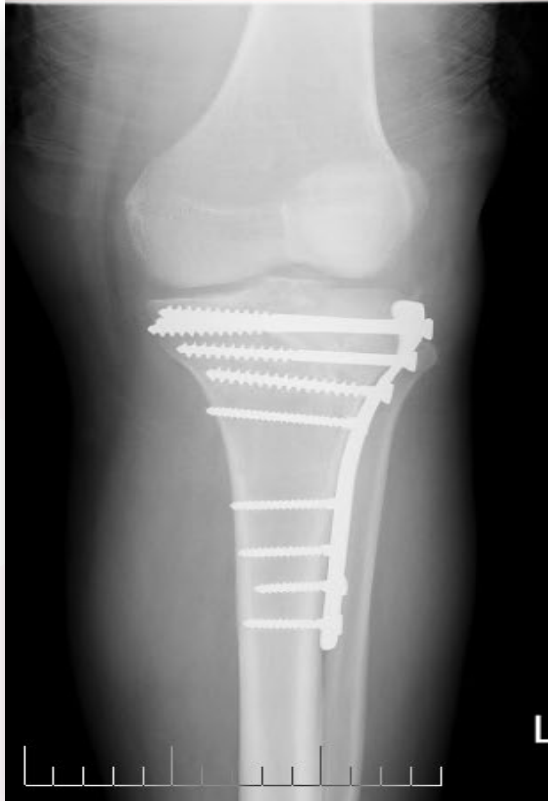What can't you see?

Case 1

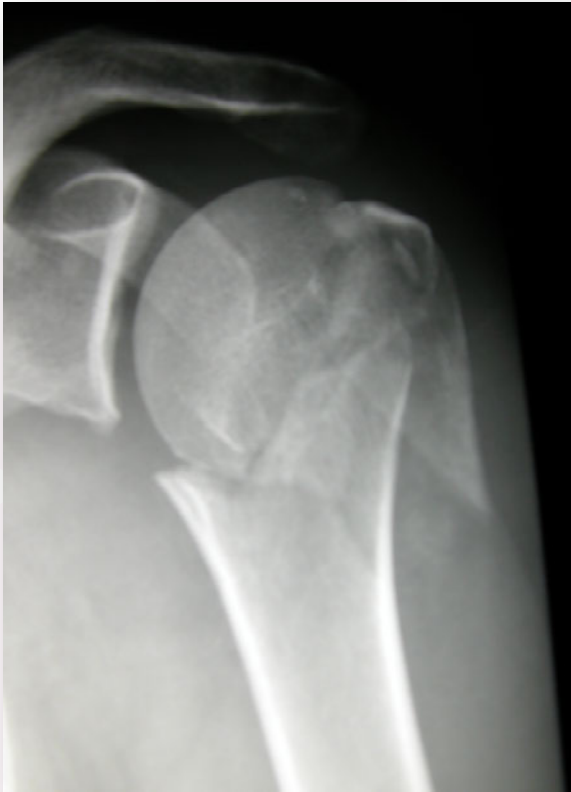

45 years old male - hit by a car
Generally in good health

Solution



Case 2

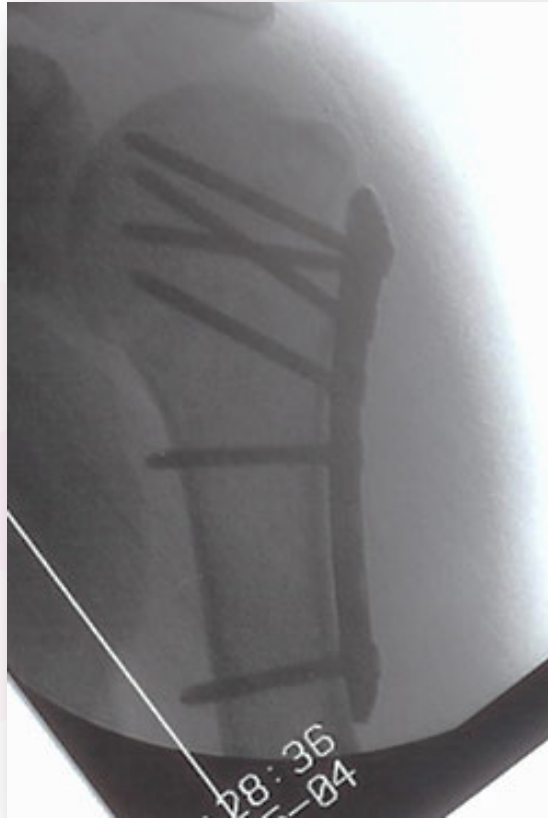


83 year old female

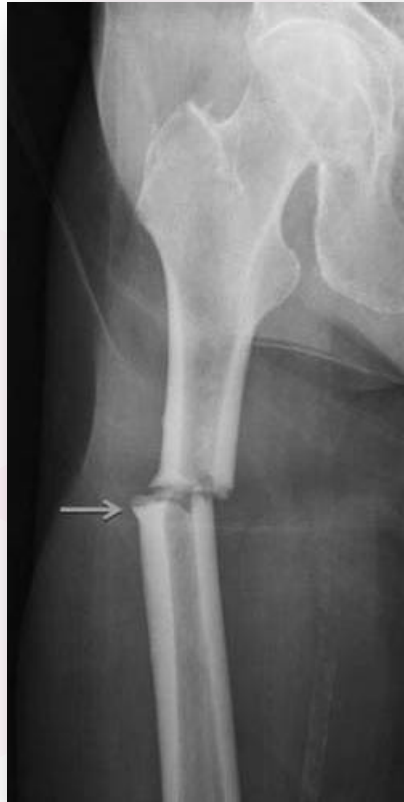Living in care home

Poor mobility

Solution



Case 3

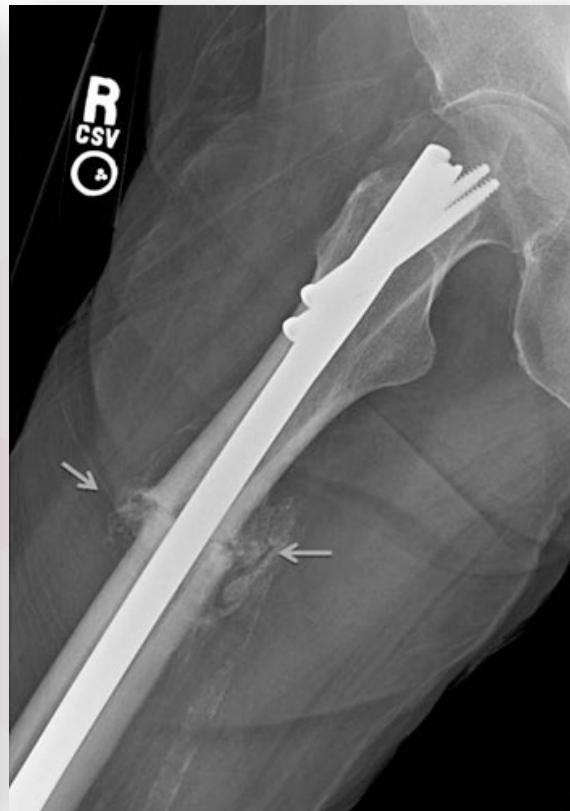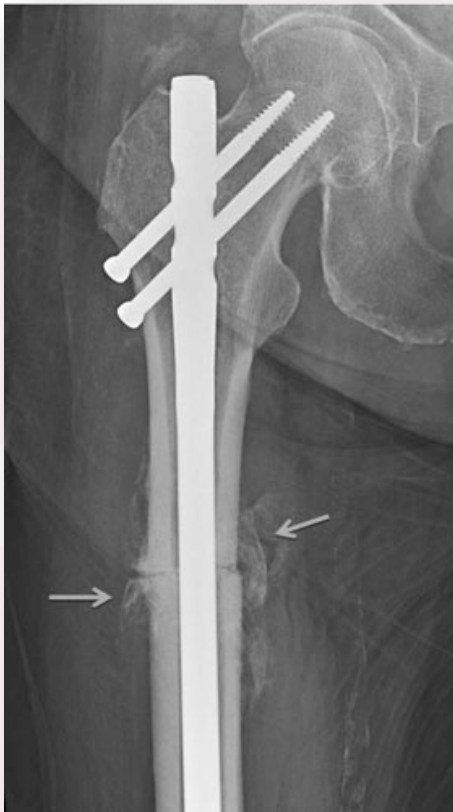


85 years old female

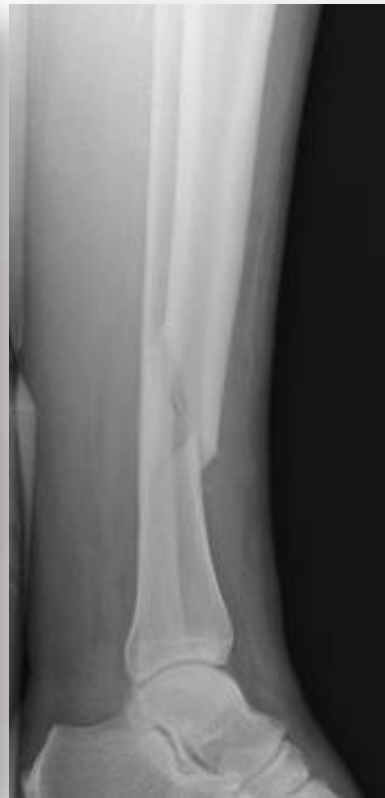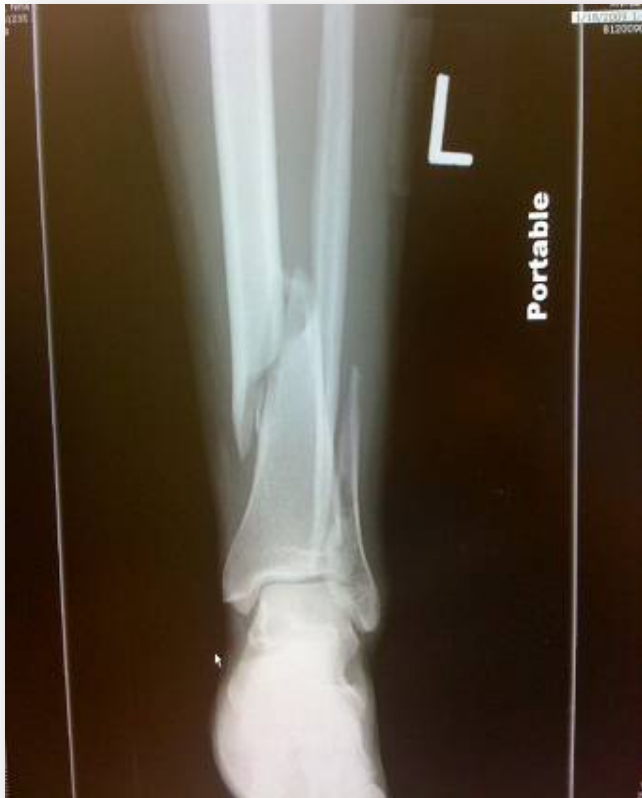Fall in Nursing Home

Osteoporotic bone

Solution



Case 4



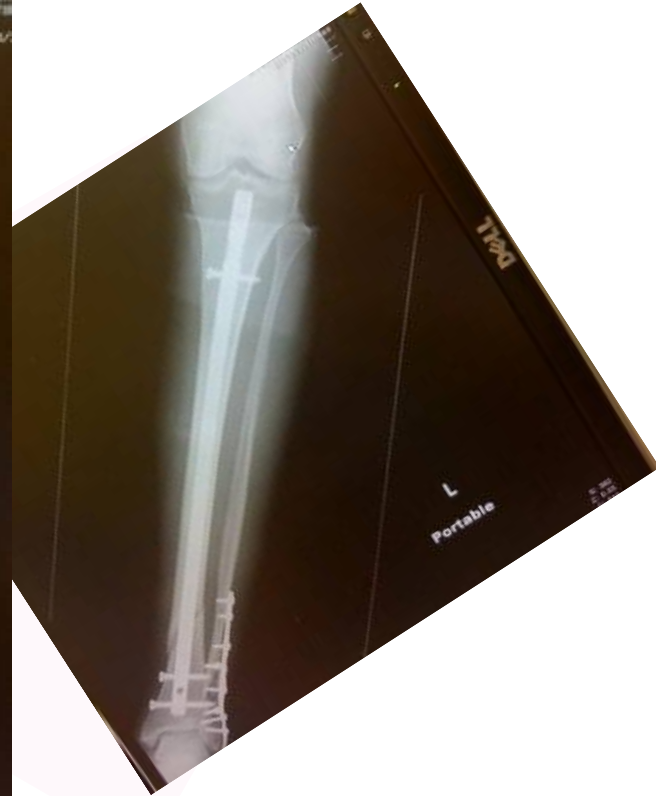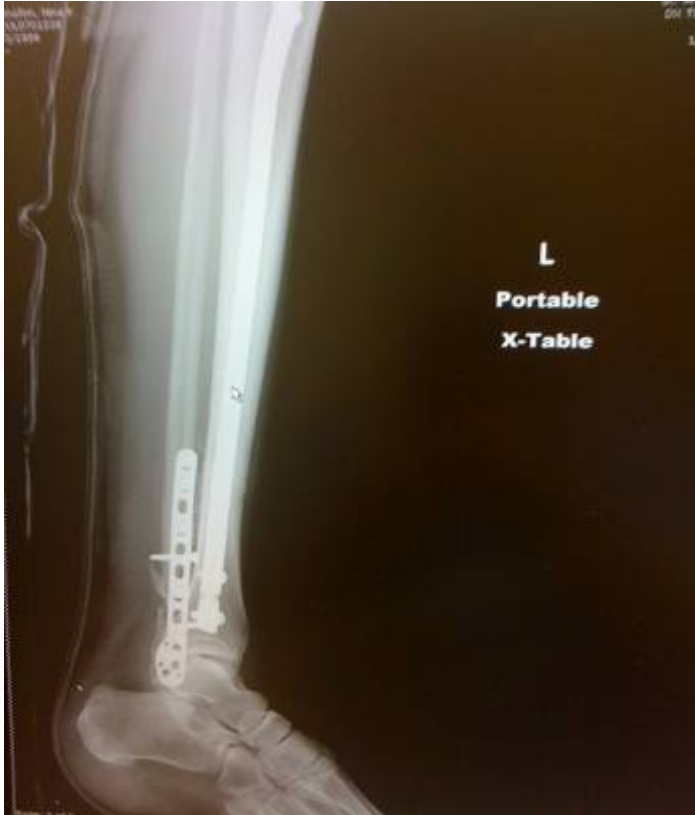32 years old

Male

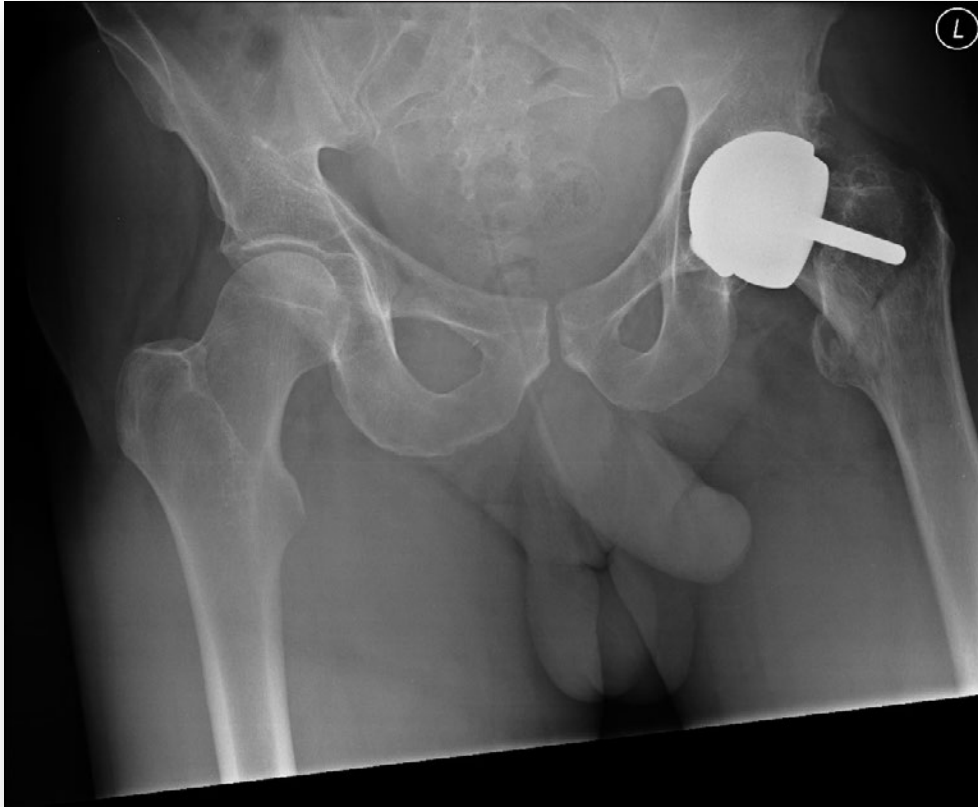Good health

Injured playing
football

Solution



Case 5

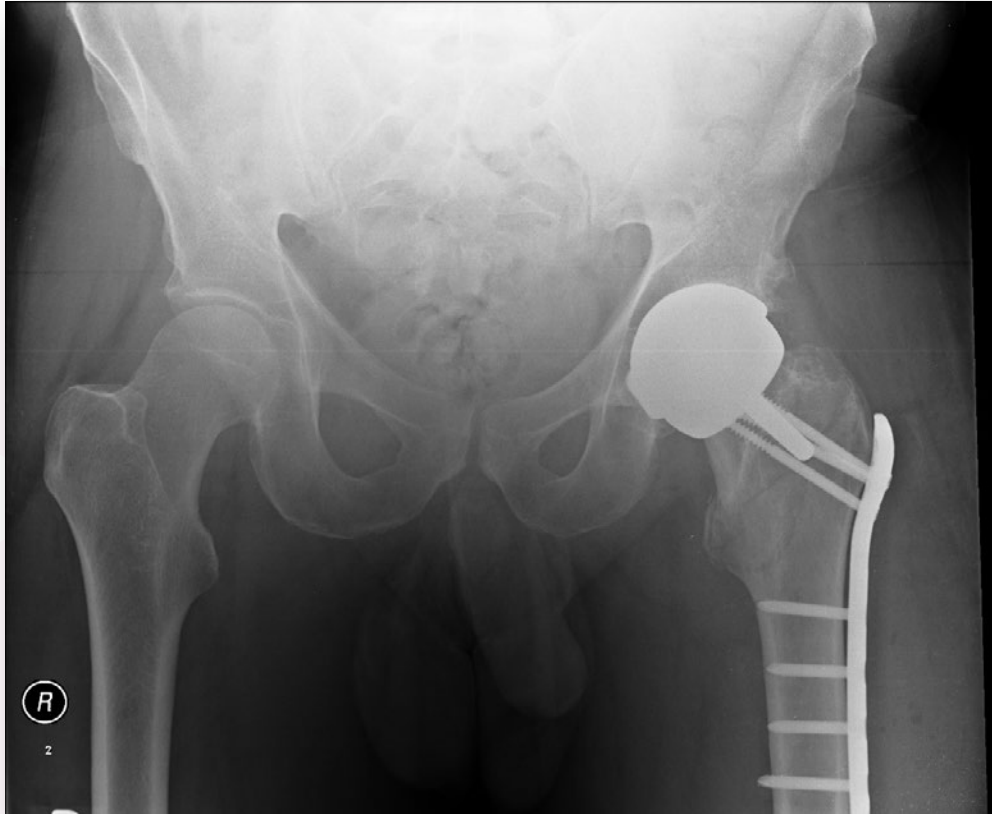


74 years old

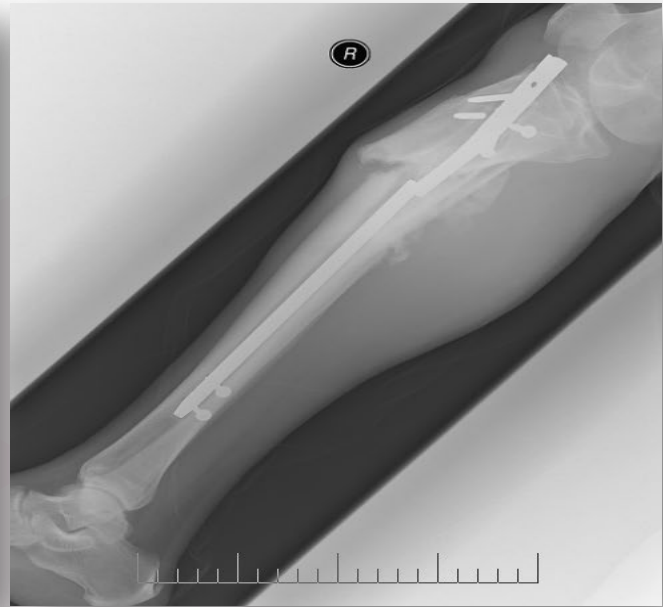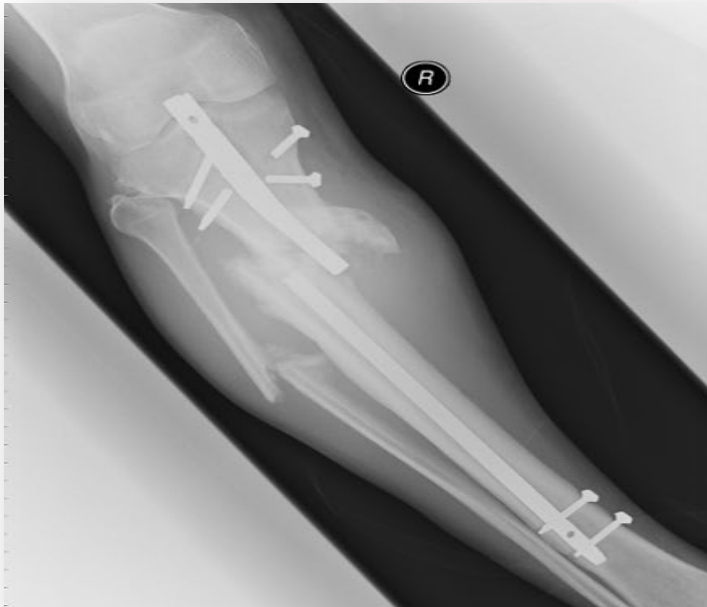
Male

No underlying
issues

Solution

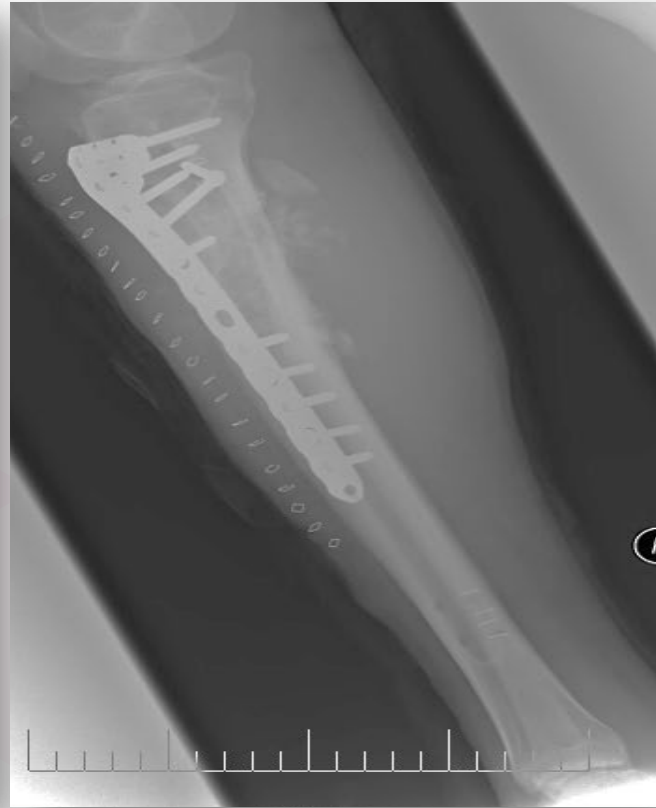
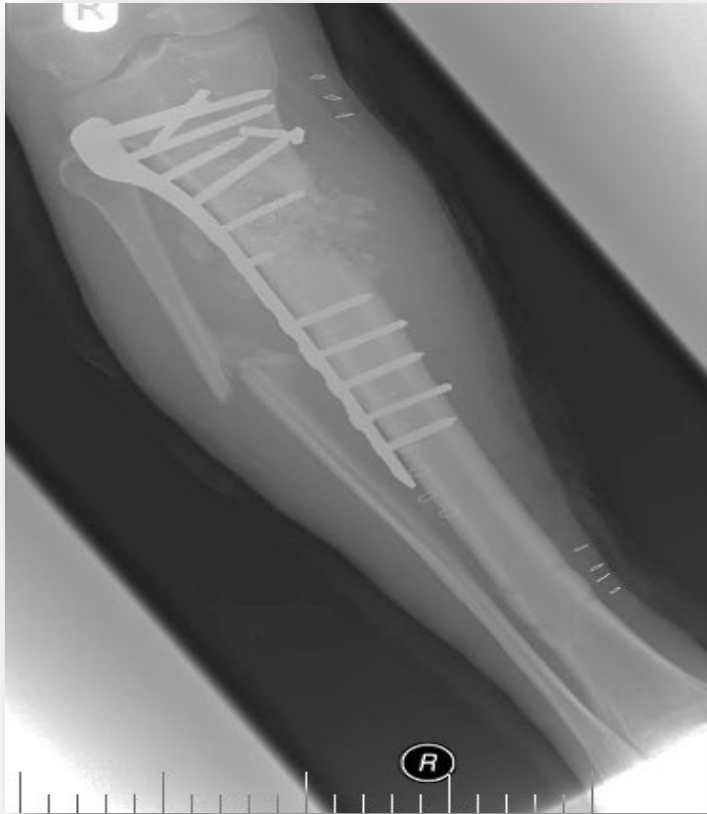

Case 6

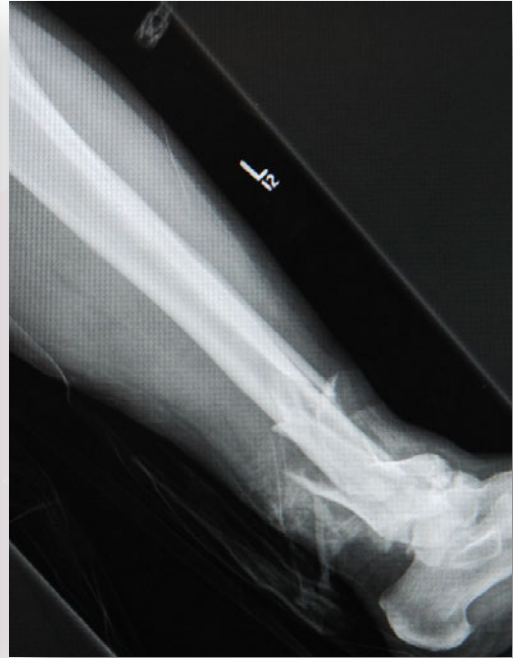
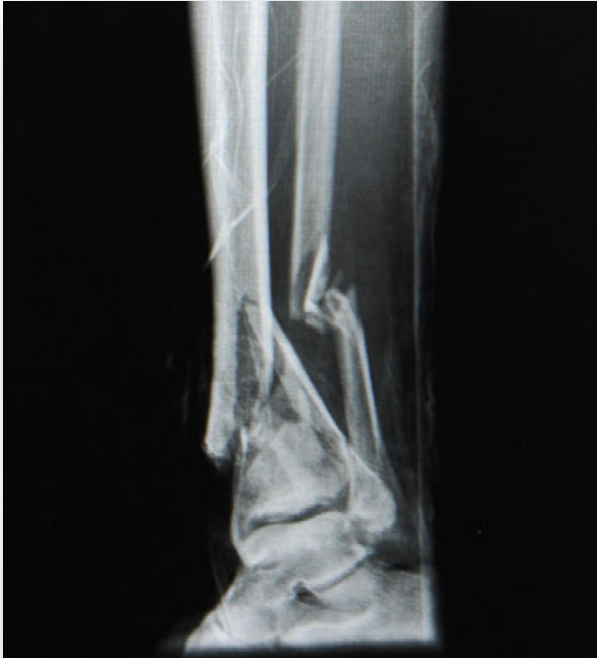
63 years old alcoholic female
No recollection of injury!

Solution

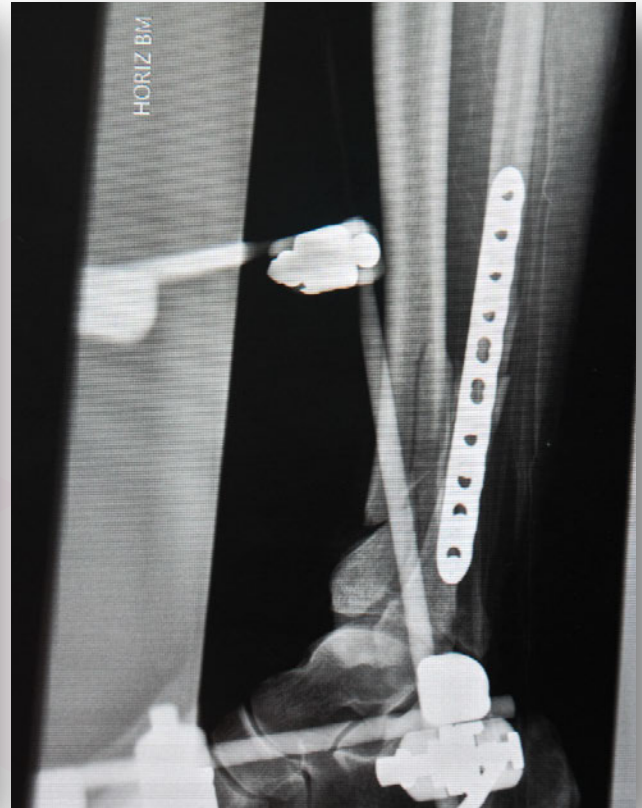
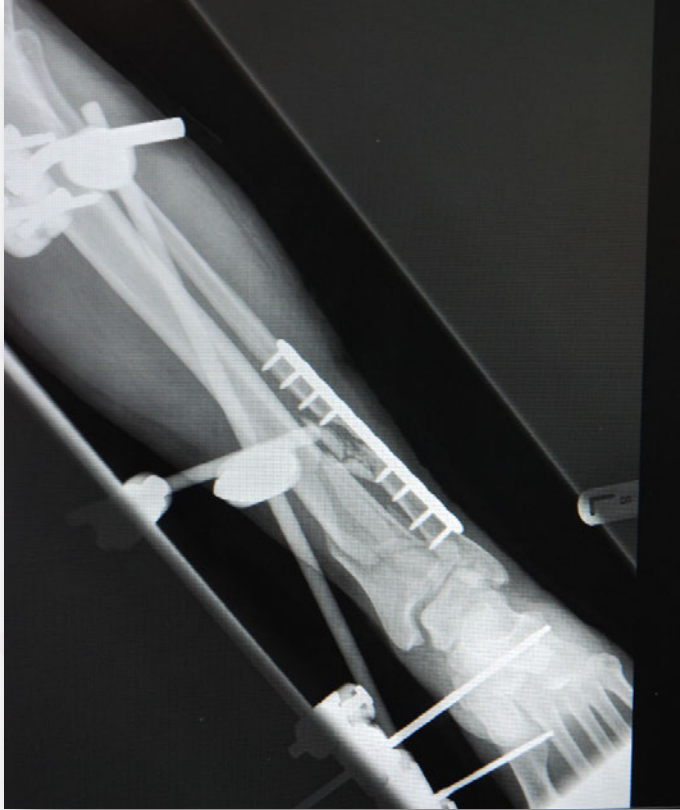
Case 7

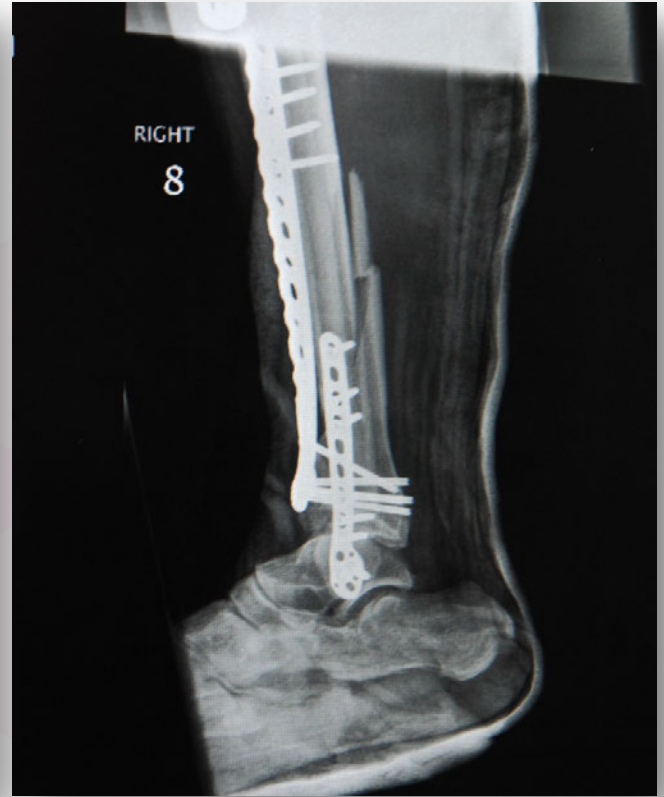
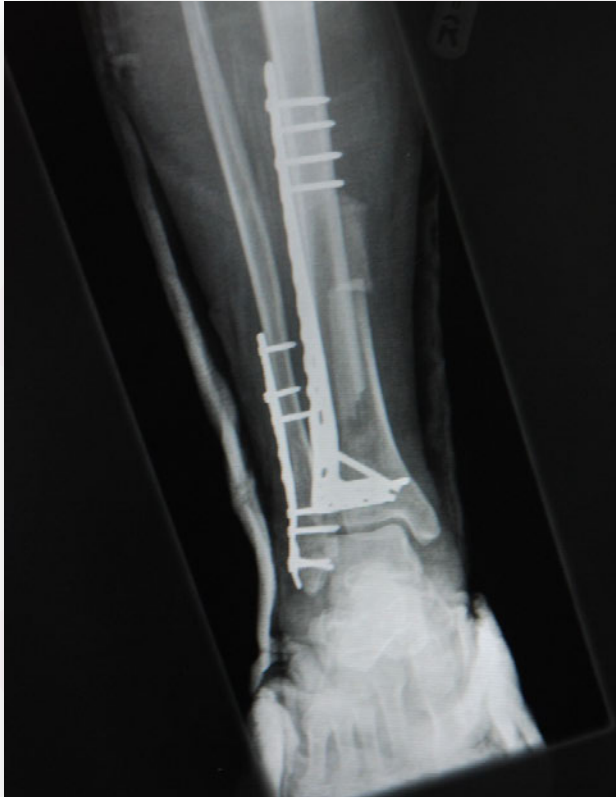
66 years old male window cleaner - recently retired
Fall from second step on ladder - otherwise in good health

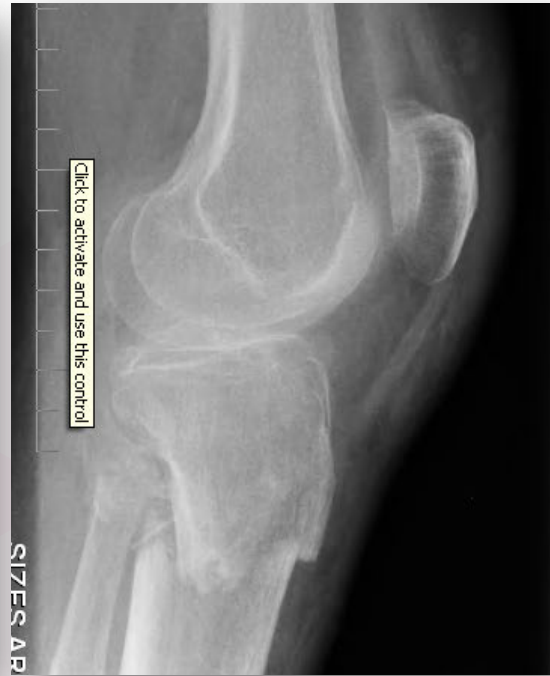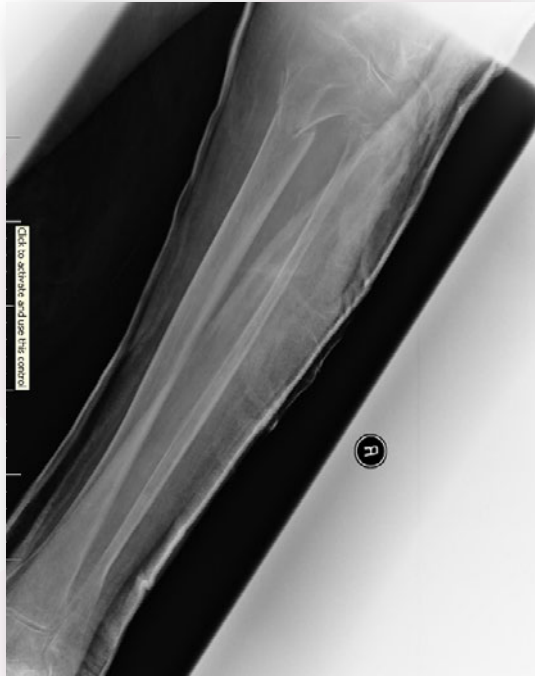Solution - left leg



Solution - right leg

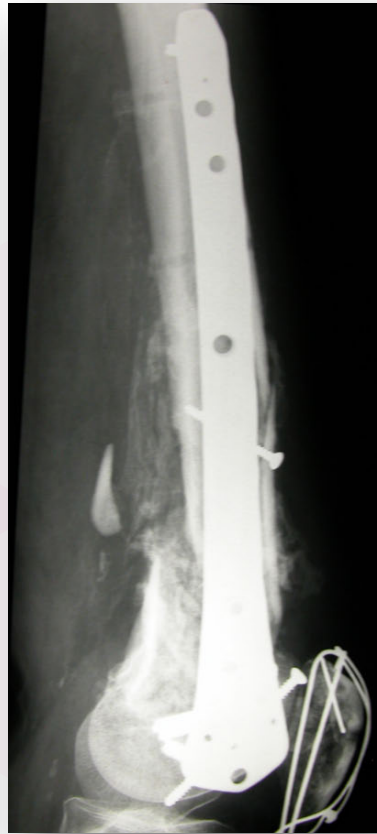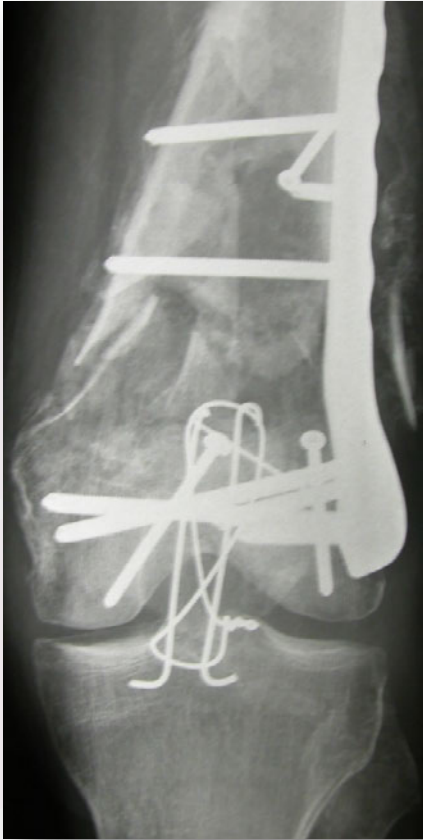


Case 8

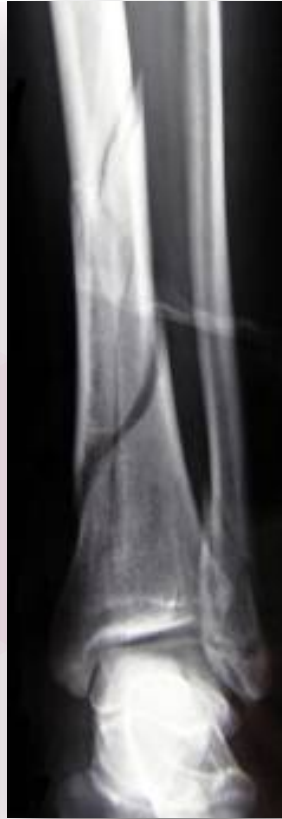
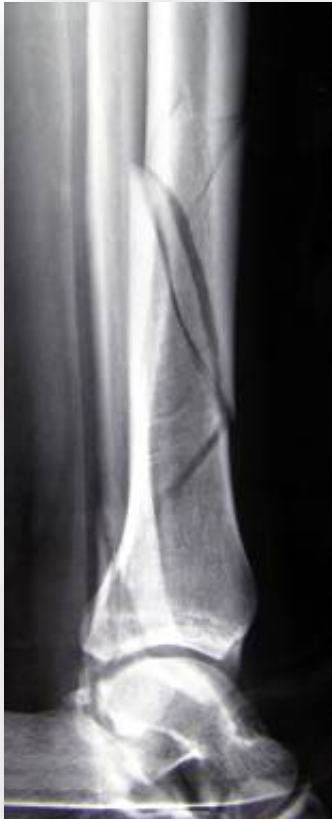
75 years female - car accident
Osteoporotic bone

Solution



Case 9

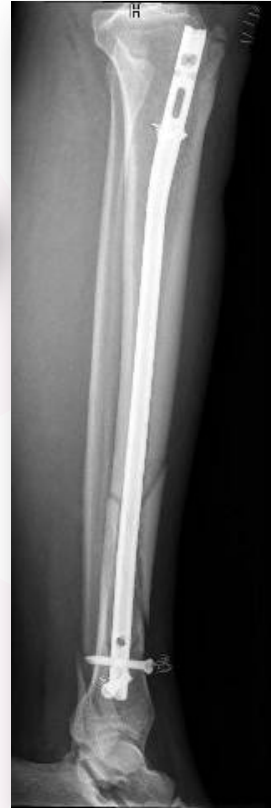
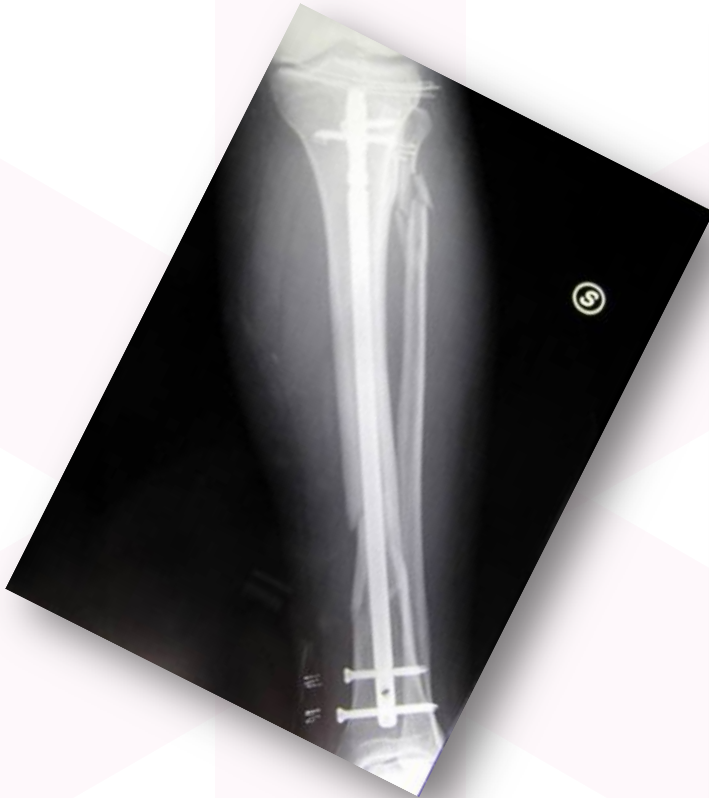
48 years old female

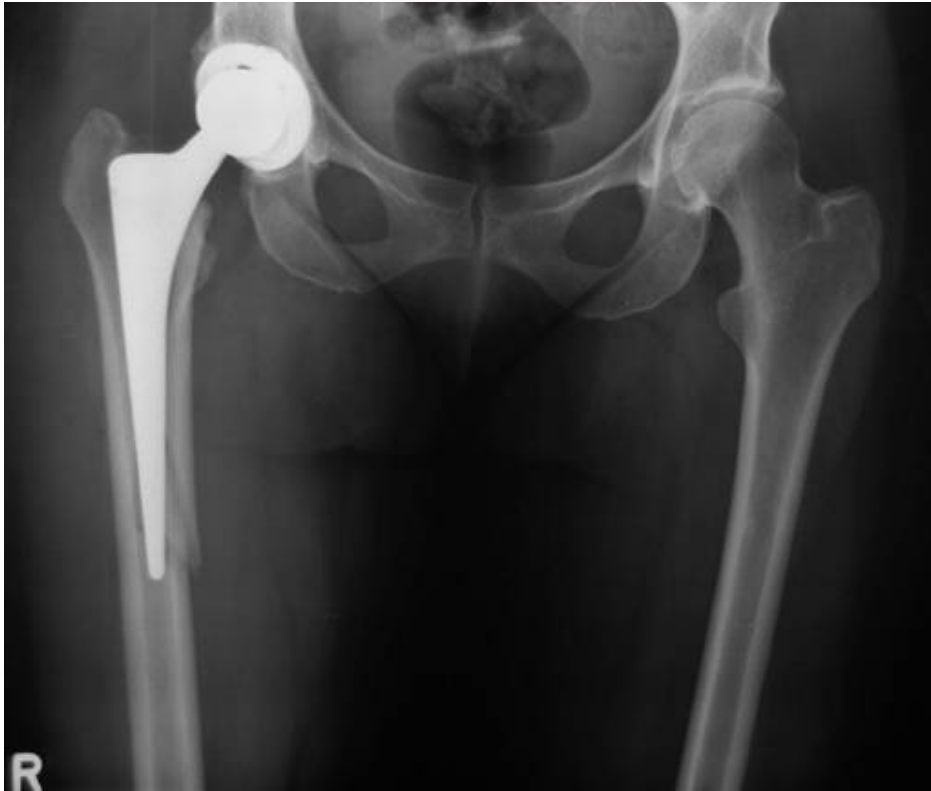Skiing accident

No known illness

Solution



Case 10

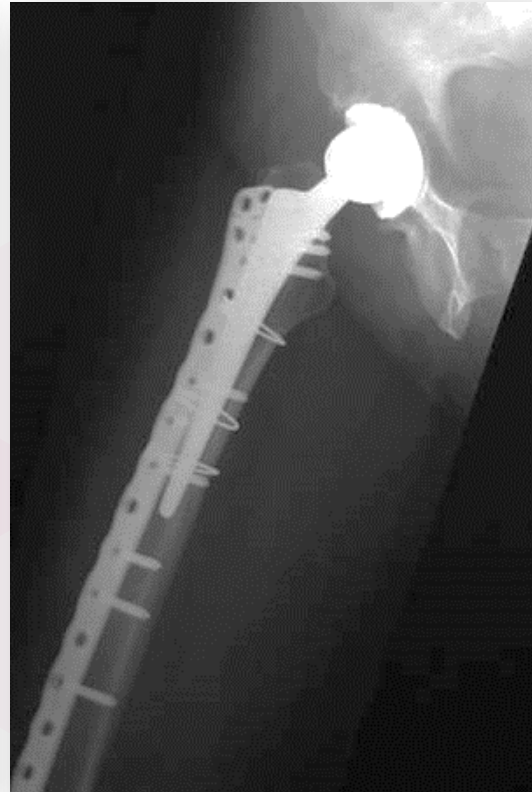
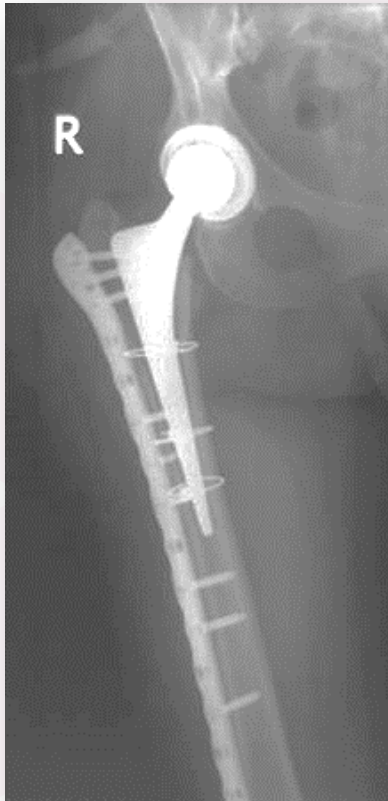
84 years old

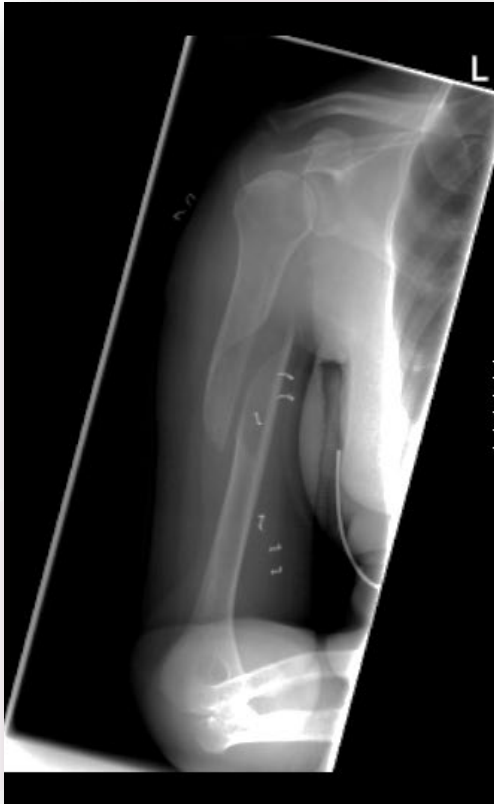Fall in garden

Good mobility

Solution



Case 11



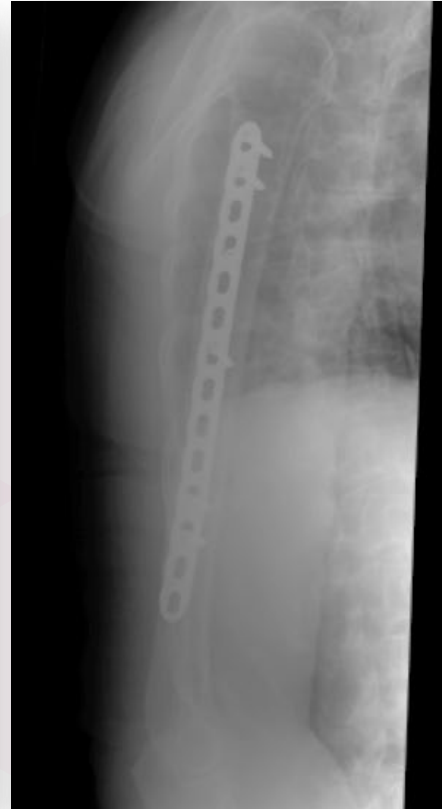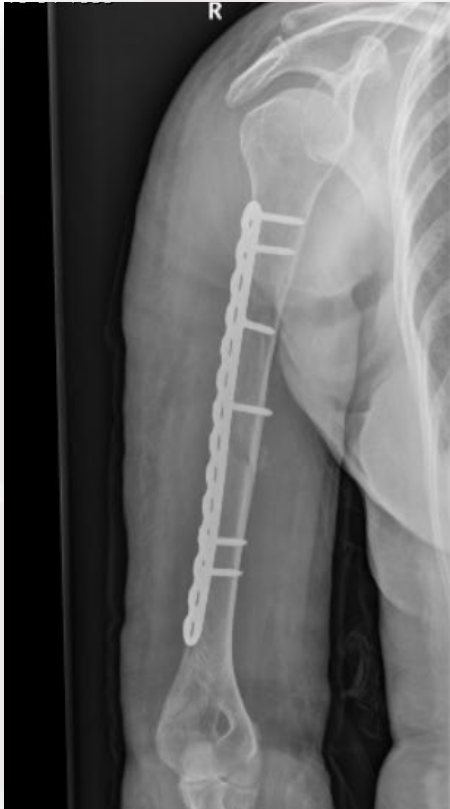78 years old

Female

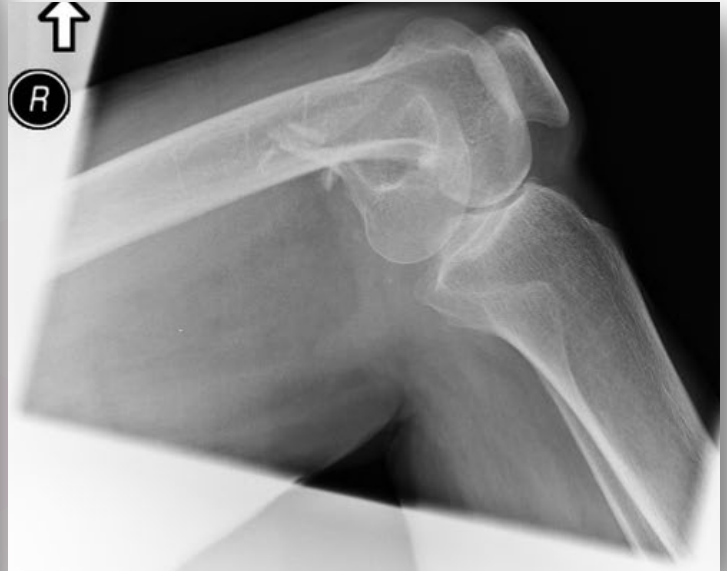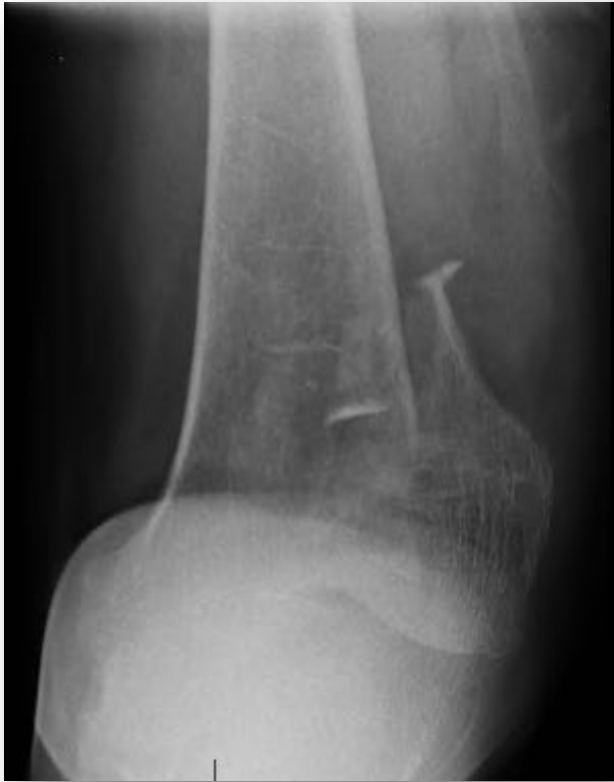Fall in home

Uses a Zimmer
frame

Solution

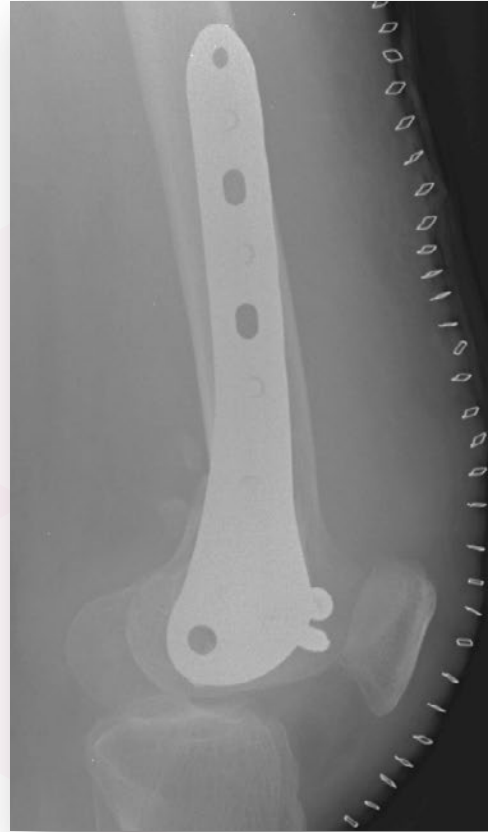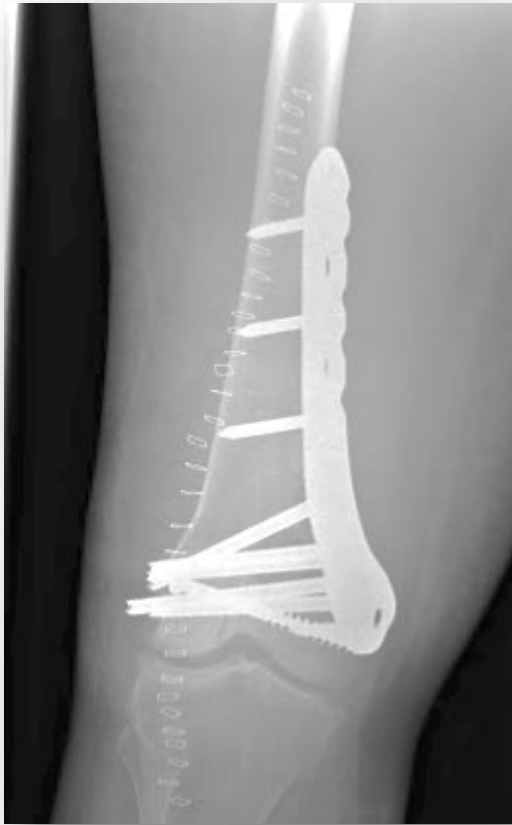


Case 12

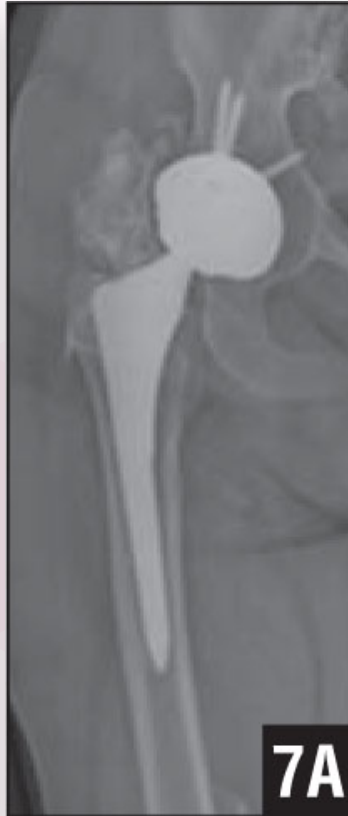
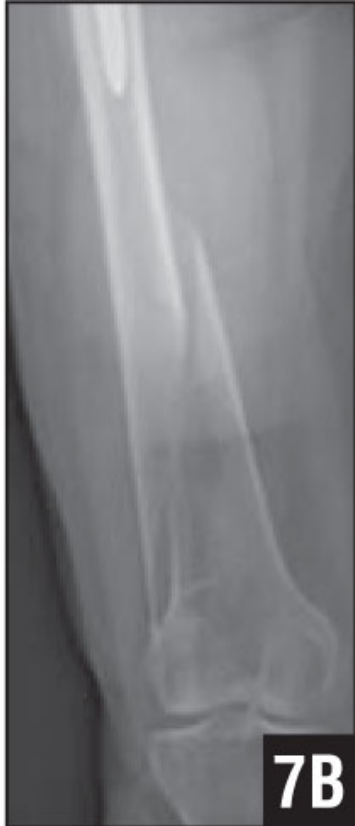
81 years old female
Fall in home

Solution



Case 12

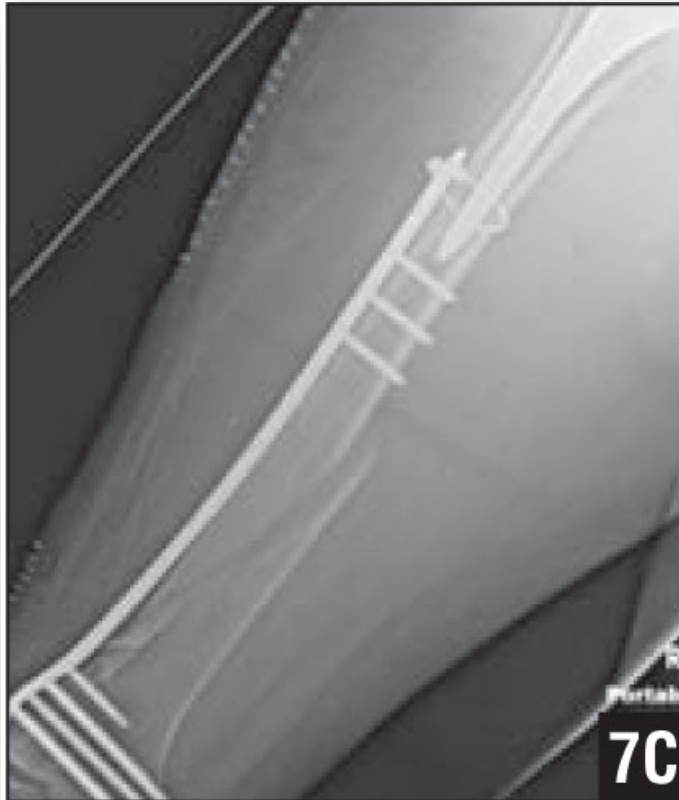

77 years old

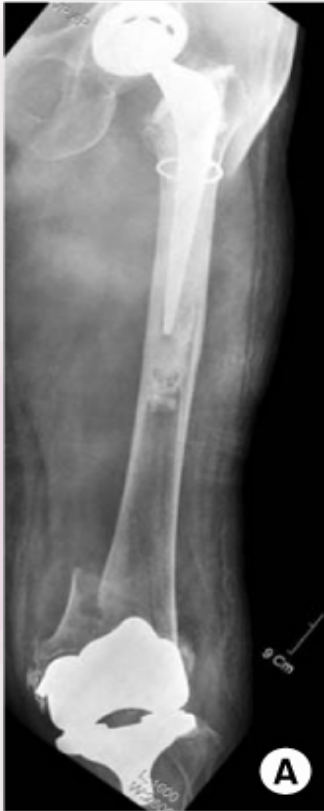Male

Fall in garden
at home

Solution



Case 13

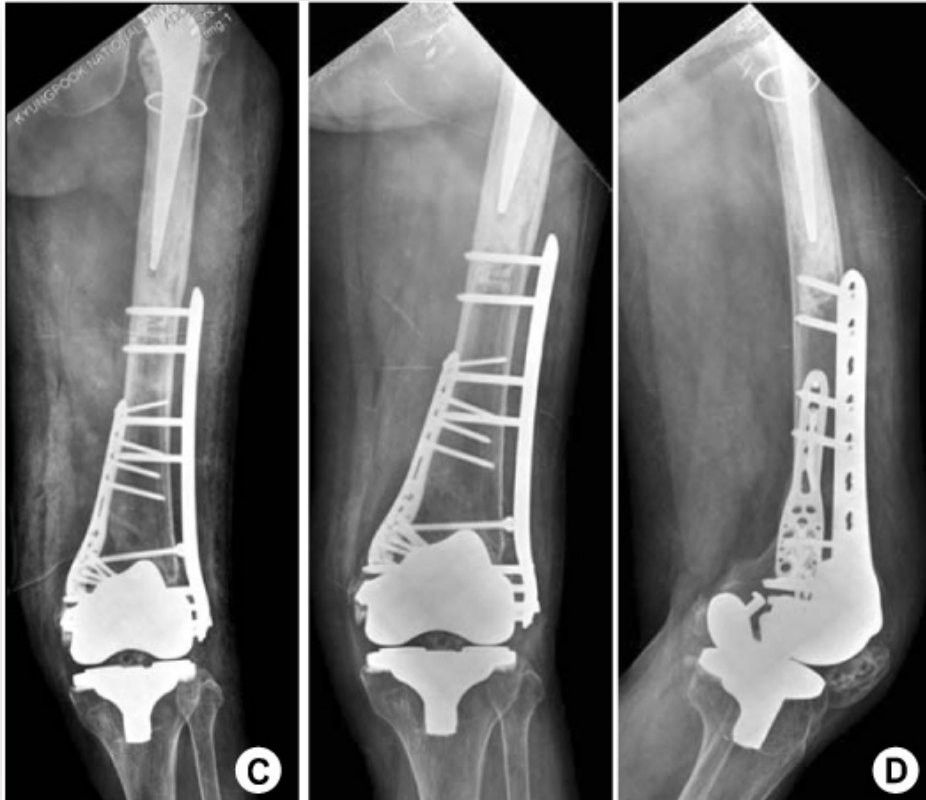

74 years old
Female

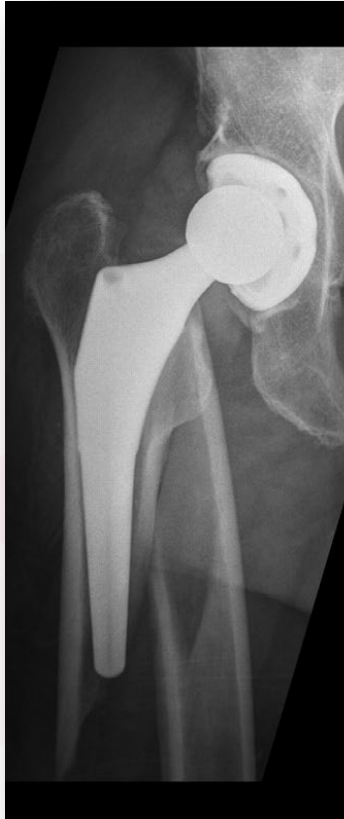Fall in care home

Osteoporotic bone

Solution



Case 14

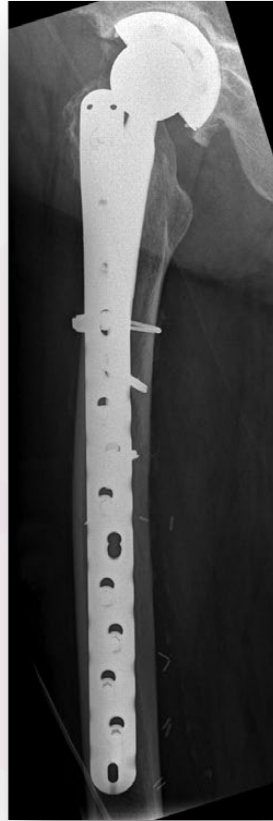
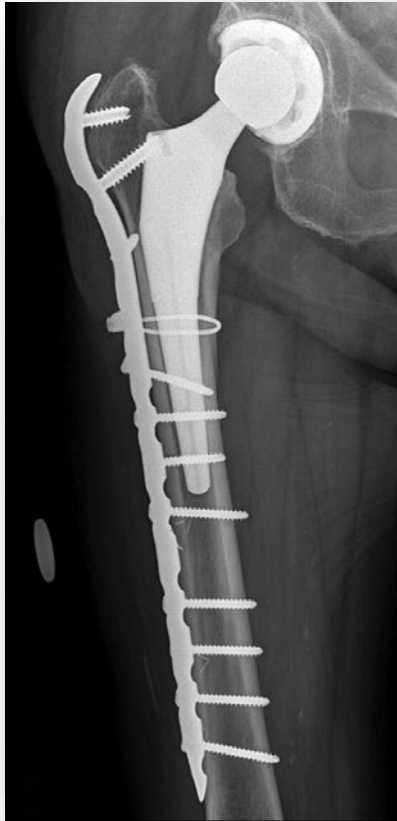
64 years old
Male

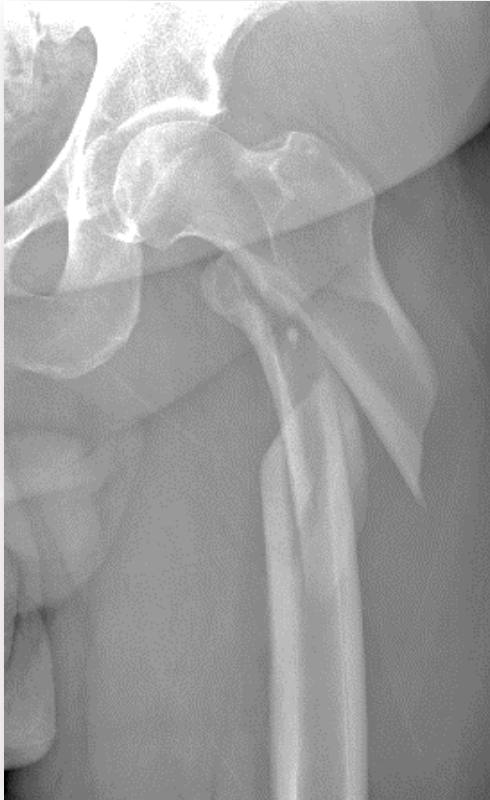
Fall whilst walking

No significant
health issues

Solution



Case 15



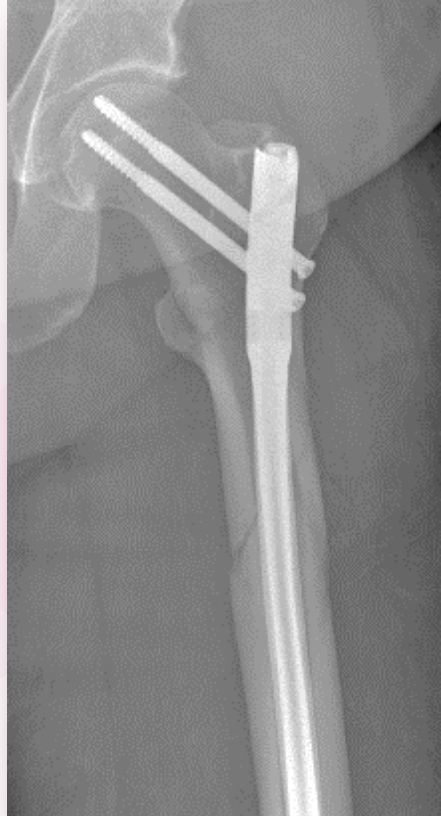55 years old
male

Hit by car

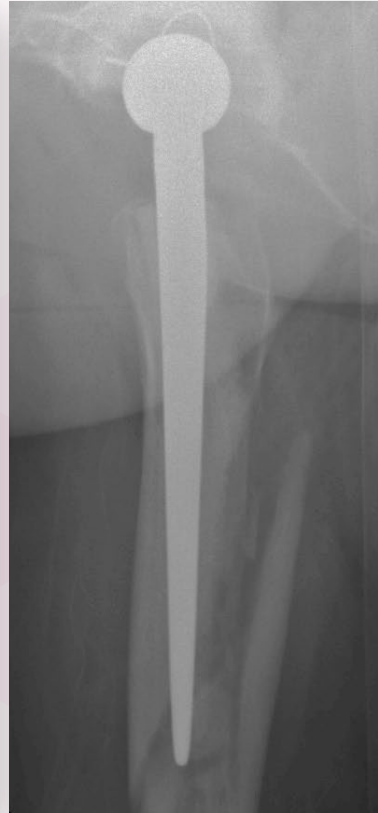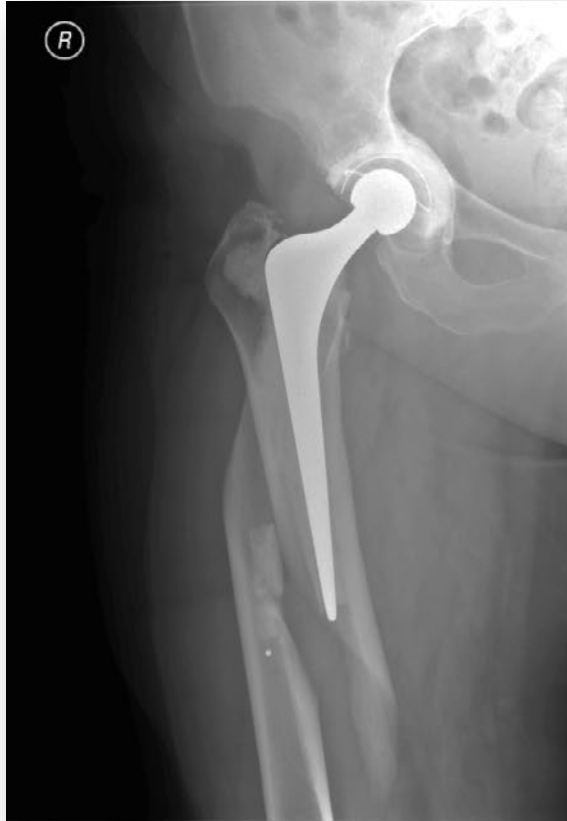Diabetic

Obese

Solution



Case 16

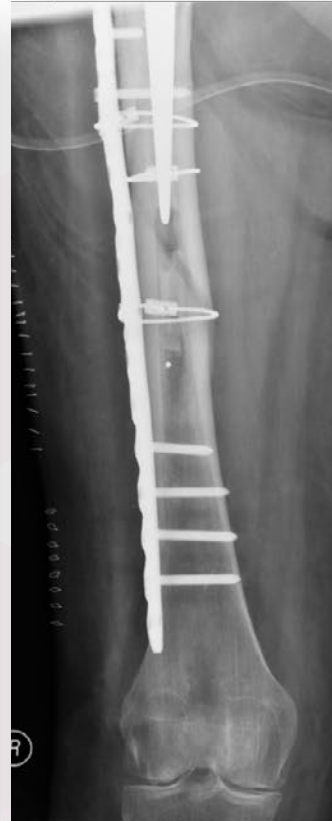
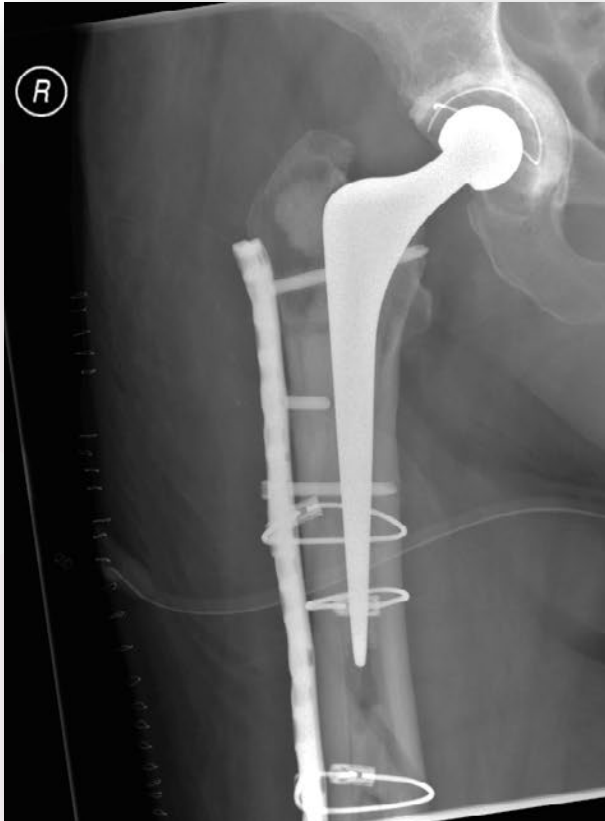
79 years old
female

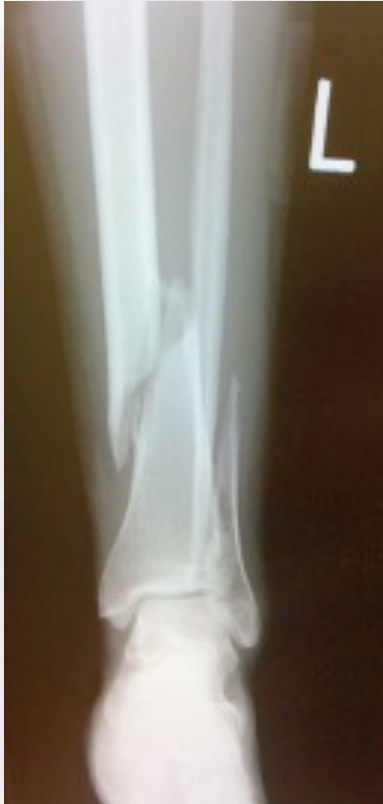Very poor
Mobility

Lives in care
home

Solution



Case 17

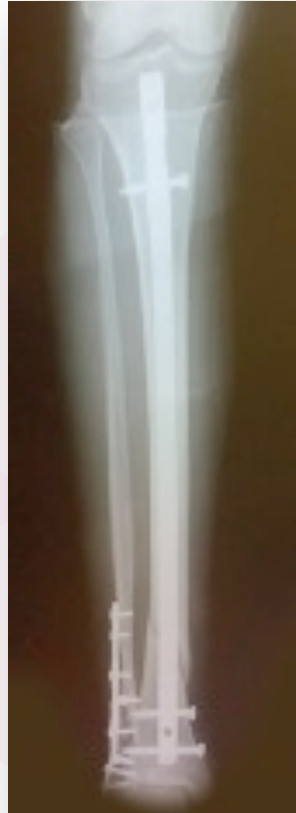
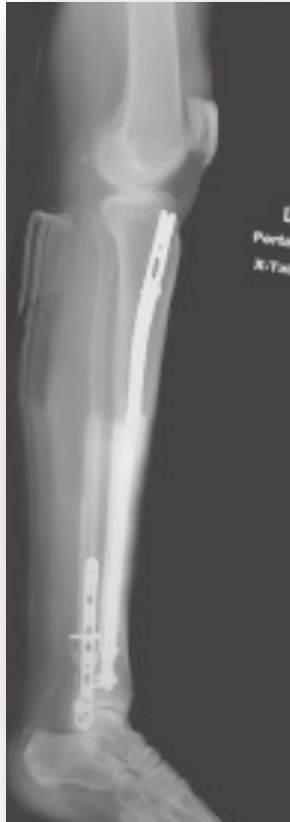
Active 21 years
old male

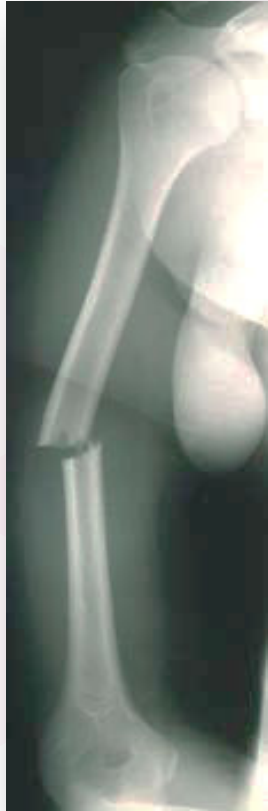Run over by
motorbike

Works as a waiter

Solution



Case 18

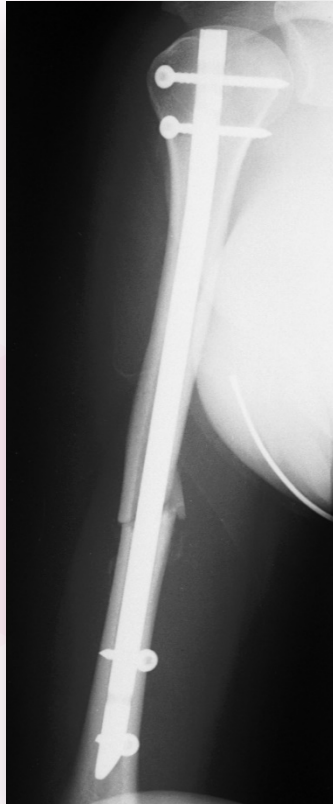

91 years old
Female

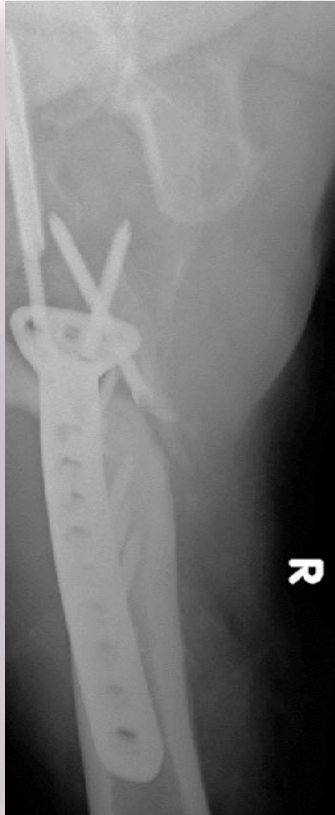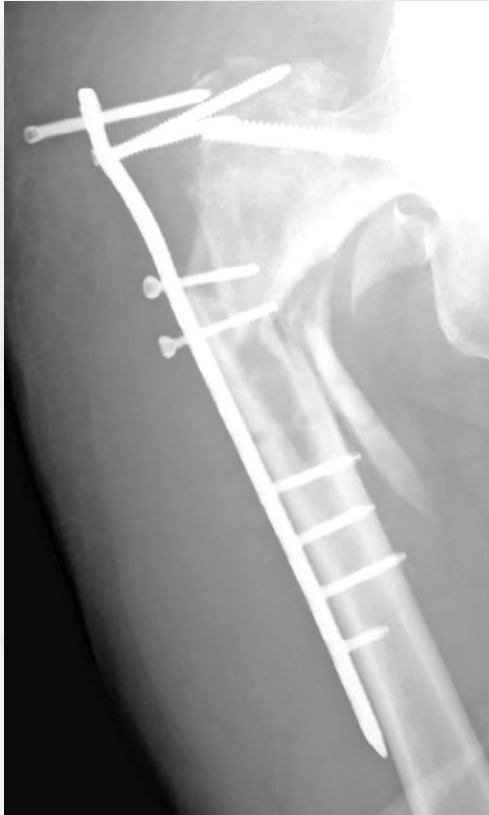Arm trapped in a
car door

Many comorbidities
including diabetes,
osteoporosis and
dementia

Solution



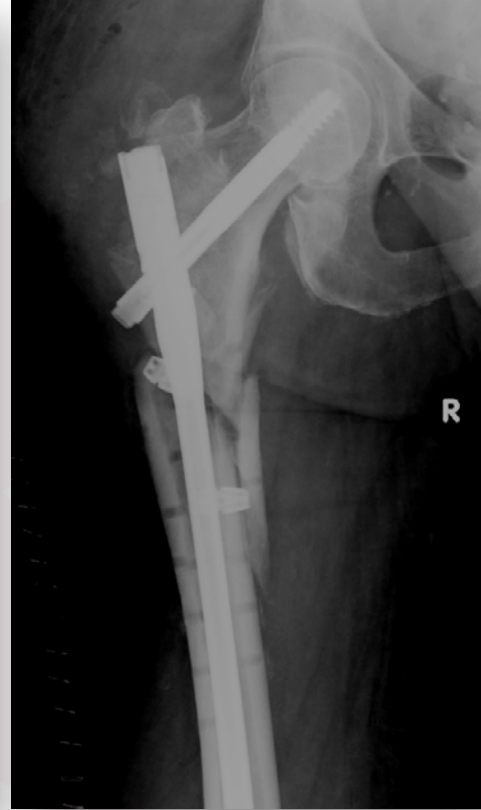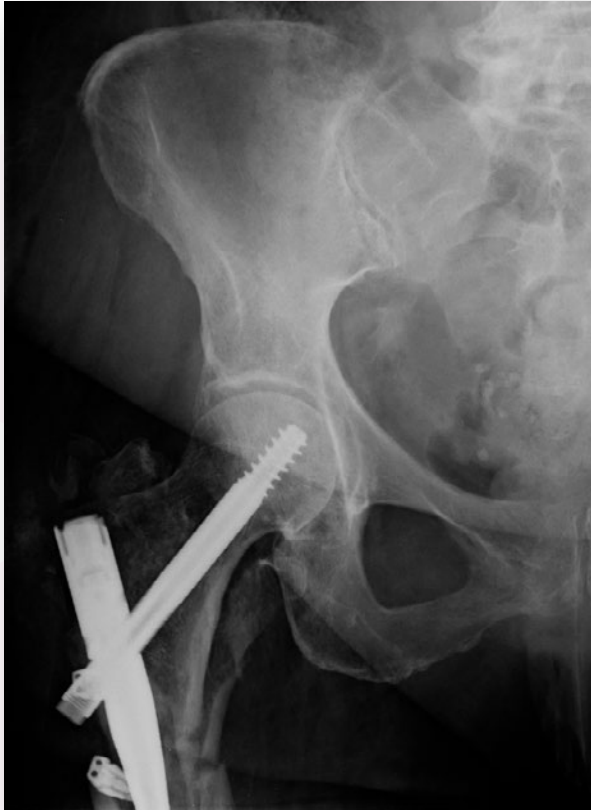Case 19



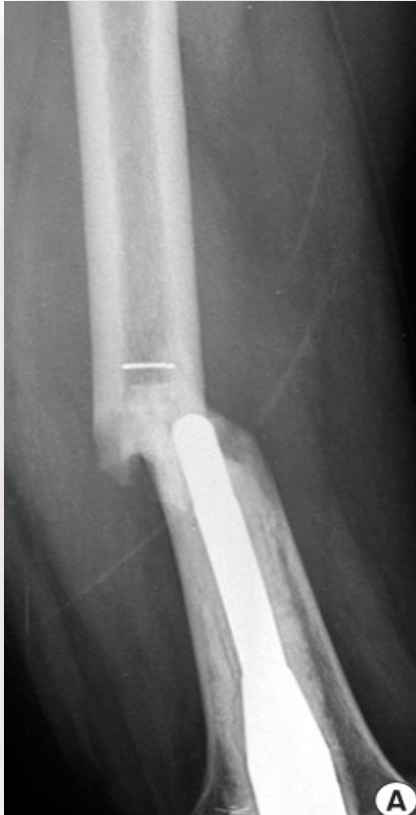75 years old male

Original DHS failed
which was revised
to this

Solution



Case 20



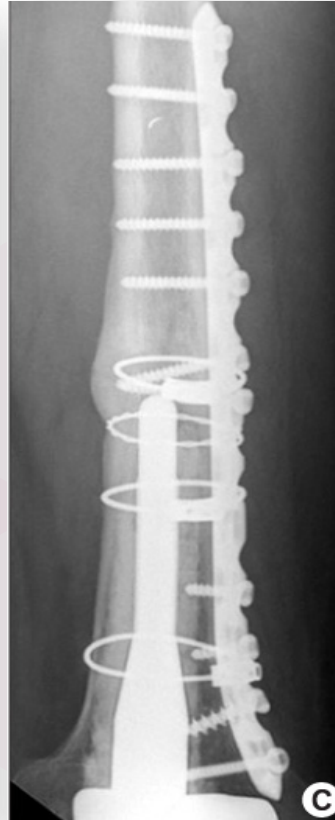
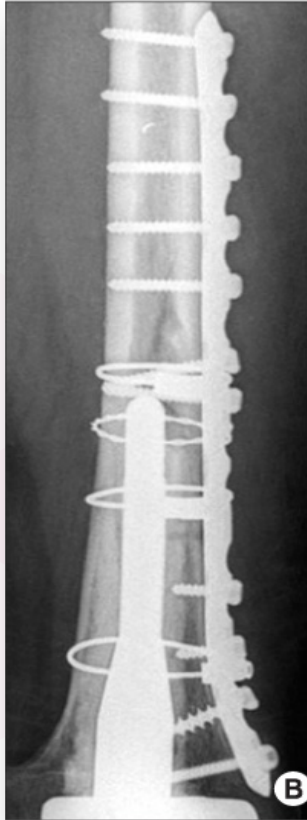
78 years old
Female

Hit by car

Osteoporosis

No other health
issues

Solution



Thank you



 **Medical Aid International**
Supporting Healthcare in Low Resource Areas 

 **ORTHOPAEDICS
INTERNATIONAL**
Part of the Medical Aid International Family